

Electrocardiograph Changes in Acute Ischemic Cerebral Stroke

Koochaki Ebrahim¹

Arami Mohamadali²

Mazoochi Majid¹

Alizargar Javad³

¹Assistant Professor of Kashan University of Medical Sciences, Beheshti Hospital

²Neurologist, Milad Hospital, Tehran, Iran

³Kashan University of medical Science, Esfahan, Iran

KEY WORDS: Stroke, Electrocardiography, Ischemic heart disease, ST segment changes

ABSTRACT

Introduction: Electrocardiography (ECG) changes are observed in patients with acute stroke and may cause diagnostic and management dilemmas. The aim of this study is to determine the frequency of ECG changes in patients with acute ischemic stroke.

Material and Methods: In a case-control hospital-based study 262 patients with cerebral infarction were observed for ECG changes during their hospitalization. The ECG changes were compared with those of the matched control group consisting of 102 individuals.

Results: Of the 262 patients of the study group, 112 (42.8%) were females and 150 (57.2%) were males. The mean age was 67.5 ± 11.9 (range 34–91 years). The control group consisted of 48 (47%) females and 54 (53%) males. The mean age was 64.5 ± 11.9 (range 31–87 yrs). The frequency of the

ECG changes observed in 179 (68.3%) of patients with cerebral infarct and 30 (29.4%) of the control group ($P < 0.001$). ECG changes observed were mostly, but not at all, related to myocardial ischemia. Inversion of T wave and ST segment changes were the most common findings and observed in 98 (37.4%) patients and 16 (15.7%) of controls. **Conclusions:** The observations of this study suggest that electrocardiography abnormalities in patients with acute ischemic stroke are common and cardiac evaluation could have prognostic importance.

INTRODUCTION

Cardiac abnormalities in patients with acute stroke were first reported in 4 patients in 1947.¹ Several studies investigated the effect of brain injury on the heart but very few studies addressed of the prognostic significance of these changes. These abnormalities can lead to diagnostic and therapeutic difficulties for cardiologists and neurologists. Khechinashvili et al. in a systematic review compiled all information available

in the literature on the prevalence of the ECG changes and QT prolongation during the acute phase of stroke and their coexistence with other abnormal cardiac findings. Abnormalities, such as ischemic-like ECG changes and/or QT prolongation were present in more than 90% of unselected patients with ischemic stroke and intracerebral hemorrhage, but the prevalence was much lower after exclusion of patients with preexisting heart disease. In patients with ischemic stroke and intracerebral hemorrhage, these ECG abnormalities (and QT prolongation) most often represent preexisting coronary artery disease. They found that the specificity of ECG changes to diagnose acute myocardial infarction is low in the acute phase of stroke.²

Dogan et al. compared the electrocardiographic (ECG) abnormalities in patients with acute ischemic and hemorrhagic stroke who had no history of heart disease. Ischemia-like ECG changes were found in 65% of ischemic stroke patients while they were observed in 57% of hemorrhagic stroke patients ($p=0.33$). Atrial fibrillation was more frequent in ischemic stroke than in hemorrhagic stroke (34% vs. 13%, $p=0.01$) patients. Individually, other ECG abnormalities were not different in both groups. They found that regardless stroke-related lesion, ECG abnormalities can be seen frequently in stroke patients without primary heart disease.³

Numerous studies have shown that mortality from all forms of ischemic cerebrovascular disease is primarily due to coronary artery disease. Thus, there is increasing interest in identifying coronary artery disease in patients with cerebrovascular disease, including those without clinical manifestations of heart disease. This case-control study investigated the prevalence of ECG rhythms and ischemic changes in acute stroke patients.

MATERIALS AND METHODS

All patients with first ever-acute ischemic stroke admitted to the neurology wards of the Shahid Beheshti Hospital of Kashan

University of Medical Sciences between January 2009 and June 2010 were evaluated for study. The control group included 102 patients admitted to ophthalmology wards for cataract surgery and matched by age and sex. Diagnosis of cerebral infarction was established in all the patients by cranial tomography (CT) and/or magnetic resonance imaging (MRI). Detailed history of hypertension, diabetes mellitus and neurological findings were recorded in all the patients. All the patients were evaluated for cardiac disease by detailed history and clinical examination. Patients with acute myocardial infarction in association with cerebrovascular accidents excluded from the study.

During 12 months, 262 consecutive stroke patients were enrolled in this study. ECG findings done on the day of admission were considered for the analysis. Consultant expert cardiologists analyzed the electrocardiographic findings and in selected cases cardiac evaluation using echocardiography and serum analysis for cardiac enzymes was done. ECG abnormalities were grouped into: pathologic Q-wave, AV block, atrial fibrillation, left ventricular hypertrophy, atrial dilatation, invert T-wave, ST segment elevation/depression, and bundle branch blocks.

To detection of underlying cardiac disease, clinical and paraclinical evaluation were done by consultant cardiologists of our center. The statistical significance was determined using the chi-square test and a p value of < 0.05 was considered significant.

RESULTS

Of the 262 patients of the study group, 112 (42.8%) were females and 150 (57.2%) were males. The mean age was 67.5 ± 11.9 (range 34–91 years). The control group consisted of 48 (47%) females and 54 (53%) males and the mean age was 64.5 ± 11.9 (range 31–87 yrs). In stroke group 138 (52.7%) patients were hypertensive and 46 (17.6%) of them were diabetic. In control group, history of hypertension was found in 39 (38.2%) cases and diabetes mellitus in 11 (10.8%) patients. The frequency of the abnormal ECG changes observed in 179 (68.3%) of patients with

Table 1- Comparison between electrocardiographic abnormalities of stroke patients and control group

Abnormality	Acute Stroke (No=262) No (%)	Control (No=102) No (%)	<i>p</i>
Pathologic Q-wave	33 (12.6%)	9 (8.82%)	<0.1
AV block	0	0	-
Atrial fibrillation	13 (4.96%)	2 (1.9%)	<0.2 †
Left ventricular hypertrophy	11 (4.19%)	1 (1%)	<0.15 †
Left atrial dilatation	13 (4.96%)	3 (2.9%)	<0.3 †
Invert T-wave	50 (19.08%)	12 (11.8%)	<0.1
ST segment elevation/depression	50 (19.08%)	5 (4.9%)	<0.01*
Left bundle branch block	32 (12.2%)	1 (1%)	<0.0001* †
Abnormal ECG	179 (68.3%)	30 (29.4%)	<0.001*

*significant

†Fisher's Exact Test

acute cerebral infarct and 30 (29.4%) of the control group ($P < 0.001$). (Table 1) The electrocardiographic changes that observed in stroke patients were: pathologic Q-wave in 10 (3.81%) patients, AV block was not seen, atrial fibrillation was found in 13 patients (4.96%), left ventricular hypertrophy in 11 patients (4.19%), left atrial dilatation in 13 patients (4.96%), invert T-wave in 50 patient (19.08%), ST segment elevation/depression in 50 patient (19.08%), and left bundle branch block in 32 patient (12.2%). Using proper paraclinical tests 9 (3.4%) patients had valvular heart disease and 27 (10.3%) of them suffered congestive heart failure. Table 1 show various electrocardiographic abnormalities which we found in evaluation of our controls and compares their frequency between two groups.

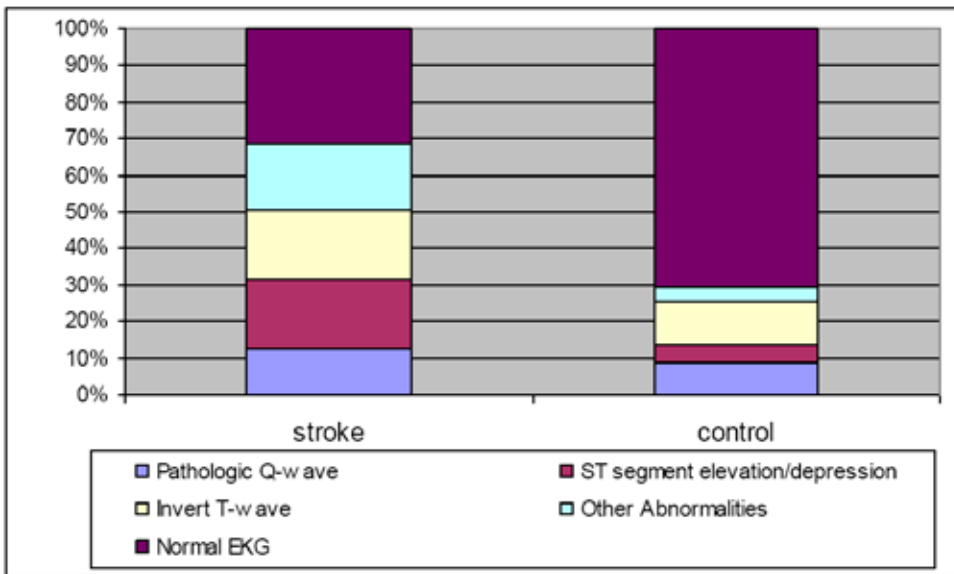
Inversion of T wave and ST segment changes were the most common findings and observed in 98 (37.4%) patients and 16 (15.7%) of controls. The observed abnormalities were mostly related to myocardial ischemia (Fig 1). Clinical and paraclinical evaluation (echocardiography, exercise test

and coronary angiographic study in selected cases) revealed underlying cardiac disease in 103 patients (39.31%) of the study group. In other 76 cases with abnormal electrocardiography (29% of all stroke cases and 42% of patients with abnormal electrocardiography), we could not reveal a cardiac disease. In most of these patients electrocardiographic changes were transient according to follow-up period recordings.

DISCUSSION

Coronary artery disease and ischemic cerebrovascular disease are leading causes of morbidity and mortality. Coronary artery disease often coexists with asymptomatic carotid artery atherosclerosis, transient ischemic attacks, or ischemic stroke. Numerous studies have shown that mortality from all forms of ischemic cerebrovascular disease is primarily due to coronary artery disease. Thus, there is increasing interest in identifying coronary artery disease in patients with cerebrovascular disease, including those without clinical manifestations of heart disease. ECG changes are common in

Figure 1- electrocardiography abnormalities in ischemic stroke patients



patients with ischemic stroke. ECG changes suggestive of ischemic heart disease were the common findings seen in our study. In a case control study on 150 patients with acute stroke, 138 (92%) showed ECG abnormalities. The most common abnormalities were: QT prolongation (68 patients, 45%), ischemic changes (59, 35%), U waves (42, 28%), tachycardia (42, 28%), and arrhythmias (41, 27%). Patients with cerebral embolus had a significantly increased frequency of atrial fibrillation (9 patients, 47%); and with subarachnoid hemorrhage an increased frequency of QT prolongation (20, 71%) and sinus arrhythmia (5, 18%). The frequencies of QT prolongation and ischemic changes related strongly to admission systolic pressure but not to mortality. Stroke patients had an increased frequency of pathologic Q waves (30 patients, 20%) and left ventricular hypertrophy (39, 26%), but these were not new findings at the time of the stroke. The results are consistent with an interaction of underlying hypertensive or atherosclerotic cardiovascular disease, sympathetic hyperactivity, and possibly myocardial necrosis, in producing ECG changes.⁴

Oppenheimer reported that the frequency of new ECG changes in patients

with acute ischemic stroke was 15 to 30% (5). McDermott showed that of 51 patients with ischemic stroke or TIA, 15 (29%) had episodes of ST segment depression (95% confidence interval, 15% to 43%), and 18 (35%) had ventricular arrhythmias (95% confidence interval, 21% to 49%). In logistic regression analysis, increasing age ($P < .02$) and a left-sided neurological event ($P < .01$) were significant predictors of ST segment depression. Also they concluded patients with acute ischemic stroke or TIA have a 29% prevalence of ST segment depression within the first 5 days after their event. In comparison, the prevalence of ST depression is 2.5% to 8% in asymptomatic adults and 43% to 60% in patients with symptomatic coronary artery disease.⁶ Jesper K. et al.¹⁵ Evaluated characteristics and prevalence of ST-segment depression and/or T-wave inversion in the resting electrocardiogram of 244 consecutive patients with acute ischemic stroke, but without ischemic heart disease. The prevalence of ST-T changes ranged from 13% to 16% and this is what to expect in the background population.

In our study 41.3% of the patients were clinically diagnosed as having a cardiac disease and in the remaining the diagnosis

was based on the ECG findings. Given the fact that these patients had no earlier history or laboratory evidence of cardiac disease, it was very difficult to determine what proportion of the ECG changes was related to acute cerebral infarction. However, the fact that ECG abnormalities observed were significantly higher in the study group when compared to the control group suggests that some of the changes observed in the study group might be related to acute cerebral infarction.

Autopsy studies of the patients following acute cerebral infarction showed myocardial necrosis and hemorrhagic lesions, referred to as “myositolisis”. These lesions were detected near the nerve endings suggesting possibly neurogenic in origin^{5,7}. Some pathologists studied coronary arteries of patients who died after ischemic stroke. Sechetto did not find coronary arterial pathology in a patient with ECG findings suggestive of acute myocardial ischemia which died due to recurrent cerebral bleed⁸. Also in another study there was no evidence of coronary artery disease at autopsy in 8 patients with ECG changes following acute stroke¹. Cardiac involvement is more common in patients with cerebral lesions involving frontal lobe, insular cortex and amygdala^{9, 10, 11, 12}.

Natelson showed cardiac arrhythmias in 51% of ischemic strokes and 15% of the control group¹³. According to Kocan, acute cerebral infarction on the heart has temporary effects¹⁴, as found in 29% of our cases.

There are some hypotheses about cardiac abnormalities during cerebral injury. The electrocardiogram changes and cardiac arrhythmias frequently encountered after stroke are not solely explicable by concomitant ischemic cardiac disease. Excessive sympathoadrenal tone is contributory. Specifically, it is now believed that augmentation of intracardiac sympathetic nerve activity occurs, producing cardiac myocyte damage and depolarizing ionic shifts, resulting in electrocardiogram repolarization changes and arrhythmogenesis. Experimen-

tal and clinical evidence now implicates the insular cortex and its subcortical connections in the generation of cardiac arrhythmias under stress and following hemispheric stroke. Lateralization studies indicate that destruction of areas adjacent to the right insular cortex, or involving noncardioactive zones within this region have especially marked cardiac effects. This very likely contributes to the cardiac mortality which is the principle long-term cause of death in stroke patients⁵.

CONCLUSIONS

The observations of this study suggest that electrocardiography abnormalities in patients with acute ischemic stroke are common and cardiac evaluation could have prognostic importance.

REFERENCES:

1. Oppenheimer SM, Hachinski VC. The cardiac consequences of stroke. *Neurol Clin* 1992; 10:167-76.
2. Khechinashvili G, Asplund K. Electrocardiographic changes in patients with acute stroke: a systematic review. *Cerebrovasc Dis.* 2002; 14(2): 67-76.
3. Dogan A, Tunc E, Ozturk M, Erdemoglu AK. Comparison of electrocardiographic abnormalities in patients with ischemic and hemorrhagic stroke. *Anadolu Kardiyol Derg.* 2004; 4(2): 135-40.
4. Goldstein DS. The electrocardiogram in stroke: relationship to pathophysiological type and comparison with prior tracings. *Stroke*, 1079; 10: 253-259.
5. Oppenheimer SM. Neurogenic cardiac effects of cerebrovascular disease. *Curr Opin Neurol* 1994; 7: 20-4.
6. McDermott MM, Lefevre F, Arron M, Martin GJ, et al. ST segment depression detected by continuous electrocardiography in patients with acute ischemic stroke or transient ischemic attack. *Stroke*. 1994 Sep; 25(9):1820-4.
7. Broderick JP. Heart disease and stroke. *Stroke* 1993; 2:355-9.
8. Cechetto DF. Experimental cerebral ischemic lesions and autonomic and cardiac effects in cats and rats. *Stroke* 1993; 23:1-6-9.
9. Oppenheimer SM, Cechetto DF, Hachinski VC. Cerebrogenic cardiac arrhythmias. Cerebral electrocardiographic influences and their role in sudden death rate. *Neurology* 1990; 47:513-9.
10. Welch KMA. Discussion. *Stroke* 1993; 24:1-11-1-12.
11. Korpelainen JT, Sotaniemi KA, Suominen K, et al. Cardiovascular autonomic reflexes in infarction. *Stroke* 1994; 25:787-92.
12. Talman WT. Cardiovascular regulation and lesions

- of the central nervous system. *Ann Neurol* 1985; 18:1-12.
13. Natelson BH. Neurocardiology. An interdisciplinary area for the 80's. *Arch Neurol* 1985; 42:180-4.
 14. Kocan MJ. The brain heart connection: cardiac effects of acute ischemic stroke. *J Cardiovasc Nurs* 1998; 13:57-68.
 15. Jesper K. Jensena,., Søren Bakb, Poul Flemming Høilund-Carlsenc, Hans Mickleya. Prevalence of electrocardiographic ST-T changes during acute ischemic stroke in patients without known ischemic heart disease. *International Journal of Cardiology* 128 (2008) 137–138